ORIGINAL ARTICLE

Profile of Human Bite Facial Injuries and Their Management

Ratnakar Sharma, Kailash Singh, Akashdeep Singh

Abstract

Human bite facial injuries pose a challenge to the reconstructive surgeons. The site of defect, the three dimensional nature of defect and the need for restoration of the cosmesis of facial unit involved is technically demanding. We describe our experience of 26 patients of human bites to the face with soft tissue loss requiring reconstruction using one or the other modality over a period of 4 years presenting to our hospital.

Key Words

Human Bite, Face, Reconstructive Modalities

Introduction

Human bite facial injuries are one of the causes of facial defects arising out of aggressive human behaviour and can involve various structures like ears, eyelids, nose, cheek and lips. (1-3) Human bites have been categorized as being dangerous bites owing to mixed bacterial flora of oral cavity. Patients presenting with human bite facial injuries usually require hospital admission for initial treatment in form of antibiotic coverage, analgesia, local wound management in the form of dressings and investigative work up for reconstruction which is cosmetically acceptable.

Materials and Methods

A retrospective study was conducted on 26 patients having suffered from human bites over face over a period of 4 years. The demographic data including age, sex, occupation, site of defect , nature of wound, time of presentation after injury and reconstructive modality were recorded and analysed. All the patients had undergone routine investigations as well as screening for HIV and Viral Hepatitis. All the patients were given antibiotic coverage against Gram +ve,Gram -ve and anaerobes as well as anti tetanus prophylaxis.

Results

A total of 26 patients with Human bite facial injuries were treated over a period of 4 years. Majority of the patients were in age group of 20- 30 years (22 patients). The youngest patient in the series was 18 years old whereas the oldest patient was 52 years old. Majority of the patients were male (24 patients). Nose was the most commonly injured facial subunit in our series (21 patients), followed by ear (3 patients), whereas lower lip bites accounted for rest of the cases (2 patients). Most of the

From the Postgraduate Deptt. of G. Surgery, Govt. Medical College Jammu, J&K - India
Correspondence to : Dr Ratnakar Sharma, Assistant Professor- Deptt. of G. Surgery, Govt Medical College Jammu, J&K -India

Table1 . Age and Sex Distribution

Age(yrs)	Males	*Females*
0-10	0	0
11-20	01	0
21-30	17	02
31-40	04	0
41-50	01	0
51-60	01	0
Total	24	02

Table.3 Mode of Reconstruction

Nasal defects (21)	Paramedian forehead flap - 16 Skin grafting – 05
Helical rim defects (03)	Retroauricular Eave's flap - 03
Middle third lip defects (02)	Primary closure after refreshing margins

Fig.1 a & b Pre-op Photograph Showing Nasal Defect Following human bite

Fig. 4 a&b Post-op photograph Showing Reconstructed Right Ala

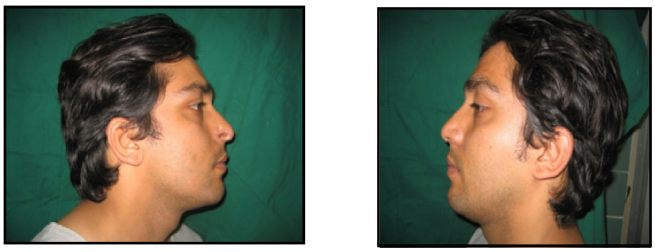

Fig.6 Pre-op photograph showing helical rim defect right ear following human bite

Table 2. Site of Defects

Nose	Ala - 17 Tip - 04	21
Ear	Helical rim - 03	03
Lower lip	Middle third - 02	02

Fig.2 a&b Post-op photograph Following Reconstruction of Nasal Defect Using Forehead Flap

Table. 3 Pre-op Photograph Showing Right Alar Defect Post Human Bite

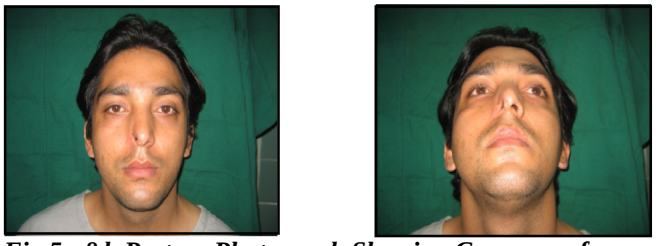

Fig.5 a&b Post-op Photograph Showing Coverage of Defect with Full Thickness Skin Graft

Fig. 7a&b Post-op Photograph Showing Helical rim Reconstruction Using Post Auricular Flap



Fig. 8 a& b Pre-op Photograph Showing Nasal Defect Following Human Bite

Fig.9 (a-c) Intraop photographs Showing Steps of Reconstruction Using left Paramedian Forehead flap

Fig.10 Post-op Photograph Showing Reconstructed Nasal Defect

patients were assaulted by military or paramilitary personnel (18 patients). The domestic violence accounted for the rest of the cases (8 patients). Out of 21 patients having sustained nasal injury, 16 patients underwent staged reconstruction using paramedian forehead flap, whereas rest of the 5 patients were managed by primary suturing or local dressings.

All the 3 patients presenting to us with helical rim injury of ear were managed by Retroauricular Eave's flap in stages.Two patients with lower lip injuries needed freshening of the margins of defect with primary closure. All the patients in our study had an uneventful healing.None of the patients in our study tested positive for HIV or Hepatitis.(*Fig.1-10*)

Discussion

Human bite facial injuries are complicated injuries with highest infection and complication rate of all mammalian bite injuries owing to wide range of bacterial flora in oral cavity (1-3). Human bites are encountered more over hand and upper limb followed by head and neck region (4). Human bite injuries are both deceptive and challenging in their presentation and management (5).

The goals of reconstruction include achieving wound closure, restoring anatomic landmarks and minimizing surgical revisions as well as psychological trauma (6).

In our study, males constituted majority of patients (11:1). Olaitan, *et al* (7) , in their study on management of human bites of face found that the males outnumbered the females.

Maximum number of patients were in age group of 21-30 yrs (73%). Datubo Brown (8) in his study of management of human bites of face found that females in the 3rd decade accounted for majority of patients.

In our study,nose was the commonest site of injury(80.76%) followed by ear (11.53%) and lower lip(7.69%). Henry FP *et al* (5) in their study on human bite injuries observed that facial injuries due to human bites accounted for 84% of the injuries with ear accounting for 66% of facial injuries followed by nose, chin, cheek and lips.

Out of 21 patients having sustained nasal injuries, paramedian forehead flap cover was employed as method of reconstruction of nasal defects in 16 cases whereas skin grafting was done in 5 patients for coverage of defects. Asuku ME, *et al* (6) employed superiorly based nasolabial flap for coverage of nasal ala defects.

In our study, retroauricular Eave's flap was employed to reconstruct the helical rim defects observed in 3 patients with no complication. Schonauer F *et al* (9) in their study of patients with helical rim defects employed

retroauricular flap for reconstruction of helical rim in 57 patients with uneventful healing in 97% of cases. Danialli L, *et al* (10) established the versatility of Post Auricular flap for helical rim defects 2.5 cm or larger.

Sinwar PD *et al* (11) has also reported that traumatic auricular amputation due to human bite is not a common event and such bite wounds are likely to be contaminated with unique poly-microbial inoculum.

02 patients in our study having sustained Middle third lip defects were managed by debridement and primary suturing . Uchendu (12) reported a five year series consisting of 37 cases of human bite to the lip. All the patients underwent primary closure of the lip defects which was successful. Healing was uneventful in all the patients in our study group with no infective complications. Lindsey D, *et al* (13) in their study of incidence of infection in cases of human bite injuries recorded the potential for infective complications to be between 10-20%. None of the patients in our study group tested positive for HIV and Hepatitis owing to human bites.

Pretty IA, *et al* (14) reported that viral transmission risk including HIV and viral Hepatitis due to human bites is a controversial subject. Hepatitis C transmission due to human bite has been documented in case reports by Figueirdo JF, *et al* (15). All the patients in our study group were administered antibiotics against Gram +ve,Gram -ve and anaerobes.Rittner AV, *et al* (15) recommended the use of antibiotics in following human bites owing to the risk of infection.

Conclusion

Human bite Is one of the most complex injuries needing specialized reconstructive procedures .Antibiotic coverage is recommended given the risk of infection.Reconstruction of the lost facial subunit and restoring the cosmesis is the primary goal in human bite facial injuries

References

1. Goldstein EJC. Bite wound and infection. *Clin infect disease* 1992;14:633-38
2. Sherman KL , Lloyd KM, Luca Pytell DM, *et al.* Treatment and outcome of human bites in head and neck. *Otolaryngol Head Neck Surg* 2003; 128:795-801
3. Ambro BT ,Wright RJ, Heffelfinger RN. Management of bite wounds to head and neck. *Facial Plastic Surg* 2010;26:456-63
4. Datubo-Brown D. Human bite of face with tissue losses. *Ann Plast Surg* 1988;21:322-28
5 Henry FP , Purcell EM , Eadie PA. The human bite injuryA clinical audit and discussion regarding the management of this alcohol fuelled phenomenon. *Emerg Med J* 2007; 24:455-58.
6. Asuku ME, Adeola DS, Obiadazie AC, *et al*. Human bites of face with tissue losses in Cosmopolitan Northern Nigeria. *Nigerian J Surg Res* 2006;8:123-27
7. Olaitan PB, Antonia O,Uduezue, *et al* Management of human bites of the face in Nigeria. *Am Health Sci* 2007; 7:50-54
8. Datubo-Brown OD. Management of human bites of the face. *Postgraduate Doctor* 1988; 10(8):233-36
9. Schonauer F, Vappalapal G, Martino S, *et al.* Versatility of the posterior auricular flap in partial ear reconstruction. *Plast Reconstr Surg* 2010;126:1213-21
10. Danialli L, Payne E,Mathew TJ. Management and reconstruction of a helical rim defect with exposed cartilage. *Jr Plast Surg* 2013;13:74-75
11. Sinwar PD. Auricle injury due to human bite - A rare case report and review literature. *Int J Surg Case Rep* 2015; 6C:5-7
12. Uchendu BO. Primary closure of human bite losses of the lip. *Plast Reconstr Surg* 1993;91(7):136-39
13. Lindsey D,Christopher M, Hollenbach J, *et al*. Natural course of the human bite wound:incidence of infections and complications in 434 bites and 803 lacerationg in the same group of patients. *J Trauma* 1987;48:2745-48
14. Pretty I A , Anderson G S, Sweet D J. Human bites and the risk of human immunodeficiency virus transmission. *Am J Forensic Med Pathol* 1999;20:232-39.
15. Figueirdo J F,Borges A S,Martinez R, *et al*.Transmission of hepatitis C but not human immunodeficiency virus type 1 by a human bite.*Clin Infect Dis* 1994;19:546-47.
16. Rittner A V,Fitzpatrick K,Corfield A. Best evidence topic report.Are antibiotics indicated following human bites? *Emerg Med J* 2005;22:654-55.